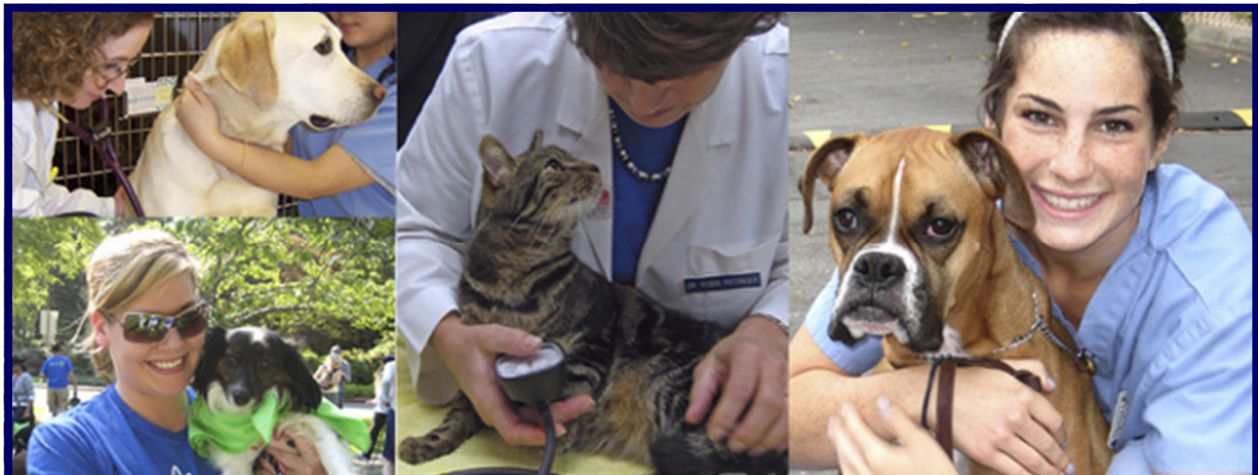



## **The most common problem in dogs and cats is periodontal disease.**

Research has shown that by age 3, 80 percent of dogs and 70 percent of cats have some form of periodontal disease, whether it be early gingivitis or severe periodontal disease. This disease can progress to deep pockets in the gingival sulcus of the teeth, leading to loss of the surrounding bone, and, ultimately, loss of teeth caused by the infection.

Dogs and cats do not show dental discomfort the same way people do because of their instinct to eat in order to survive. We know that these dental problems do cause them pain, just as it does in people, and that is why it is so important to do a thorough dental cleaning and evaluation under anesthesia.

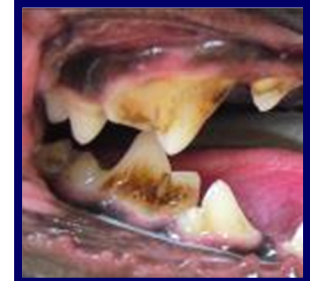

# Four Stages of Periodontal Disease

## **Gingivitis**

### GRADE ONE

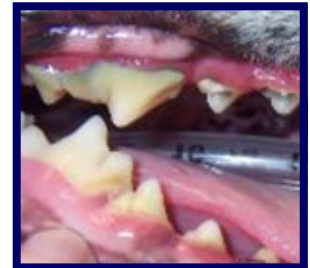- Light brown tartar on teeth; no damaged teeth
- No or very minor red gums; minimal mouth odor



## **Early Periodontitis**

### GRADE TWO

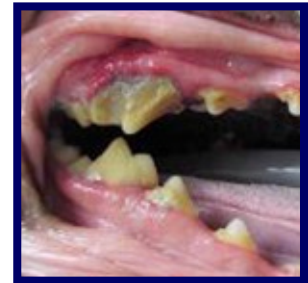- Brown tartar on teeth; +/- damaged teeth
- Red gums, but no gum recession; some mouth odor



## **Moderate Periodontitis**

### GRADE THREE

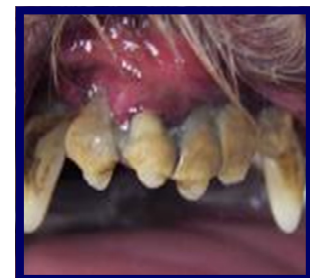- Heavy tartar on teeth; significant odor
- Red gums and gum recession
- Loose or infected teeth; Extractions anticipated



## **Advanced Periodontitis**

### GRADE FOUR

- Heavy tartar & calculus formation
- Pus in the mouth; severe gum recession
- Many loose and infected teeth
- Multiple extractions expected

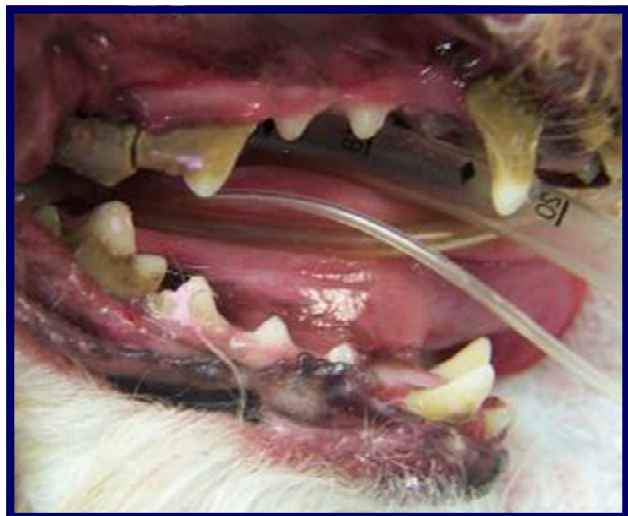

## Other Health Issues Caused by Dental Disease

Periodontal disease, caused by bacteria and their toxins destroying the teeth and gums, can cause other health problems for pets.

Every time a dog or cat inhales, they are inhaling bacteria and toxins into their lungs. Whenever they swallow, they are swallowing bacteria and bacterial toxins into their stomach and intestines.

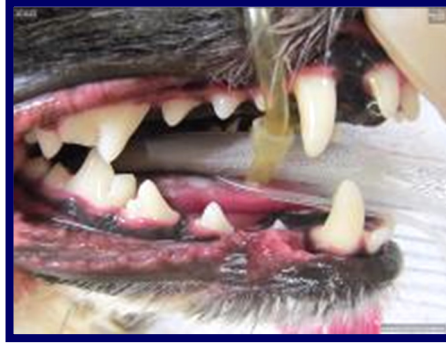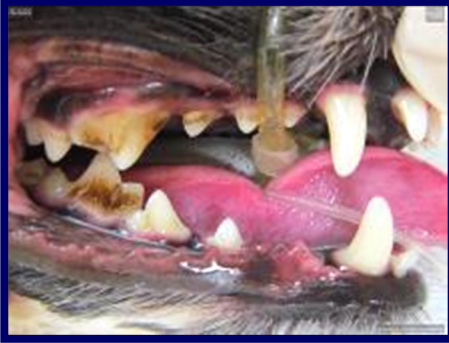Whenever they eat, bacteria and their toxins enter the bloodstream. Over several months or years, these bacteria and toxins can cause heart, liver, kidney, lung and gastrointestinal disease or organ failure. These problems become more severe as the pet ages due to chronic system changes, and chronic wear and tear on aging organs that may not be able to handle this constant load of bacteria and bacterial toxins.



# Before & After Photos

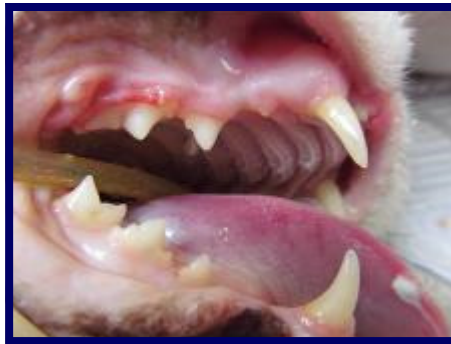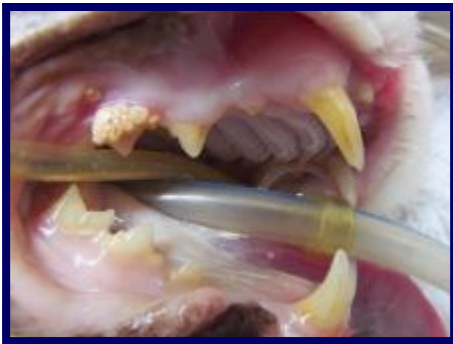
## **3 yr old / 13 lb. Short-Hair Havanese Dog —** GRADE ONE

Light brown tartar on teeth; no damaged teeth  
No or very minor red gums; minimal mouth odor



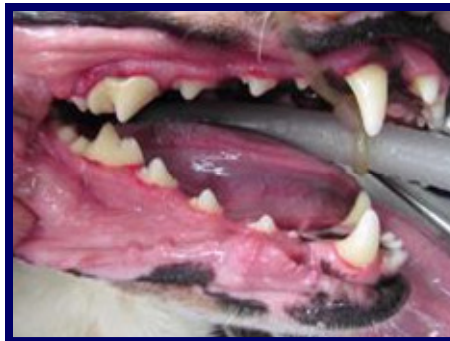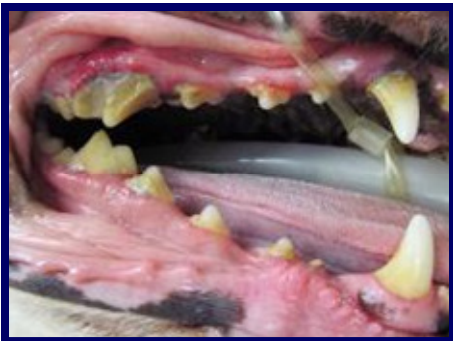## **11 yr old / 9 lb. Scottish Fold Cat —** GRADE TWO

Brown tartar on teeth; +/- damaged teeth  
Red gums, but no gum recession; some mouth odor



## **7 yr old / 55 lb. Border Collie Mix Dog —** GRADE THREE

Heavy tartar on teeth; significant odor  
Red gums and gum recession  
Loose or infected teeth; Extractions anticipated



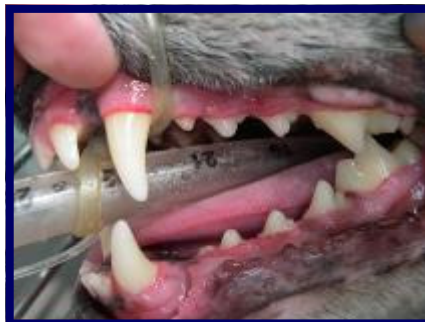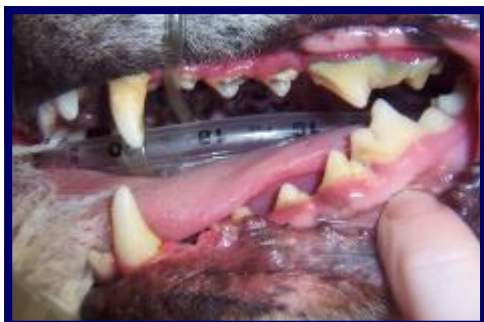## Before & After Photos

### **7 year old / 40 lb. Corgi Mix Dog —**

GRADE TWO

Brown tartar on teeth; +/- damaged teeth

Red gums, but no gum recession; some mouth odor



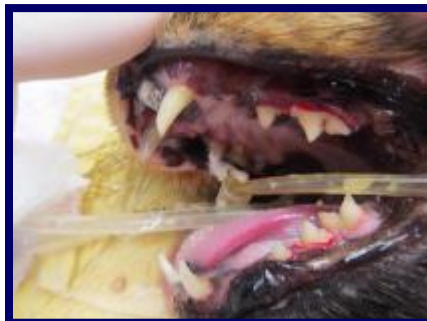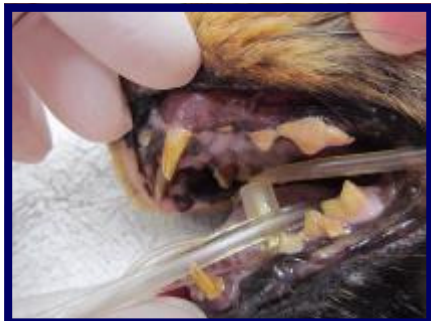### **16 year old / 10 lb. Domestic Shorthair Cat —**

GRADE THREE

Heavy tartar on teeth; significant odor

Red gums and gum recession

Loose or infected teeth; Extractions anticipated



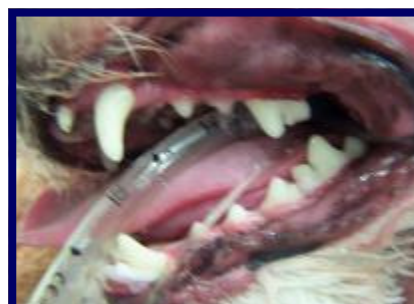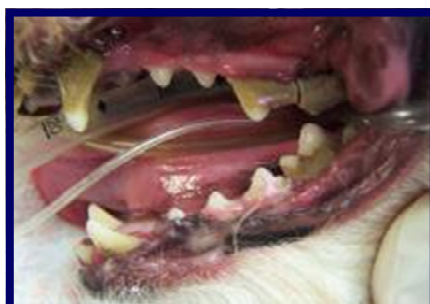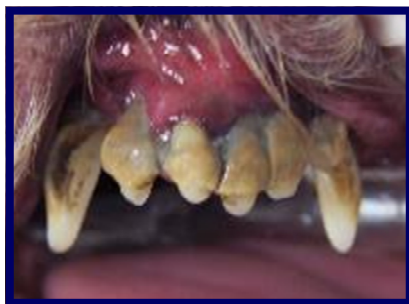### **7 year old / 10 lb. Cockapoo Dog—**

GRADE FOUR

Heavy tartar & calculus formation

Pus in the mouth; severe gum recession

Many loose and infected teeth



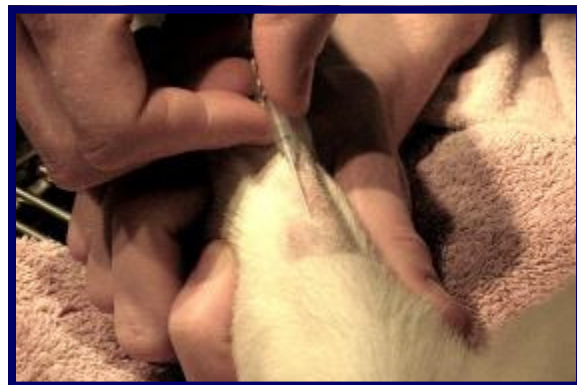# Procedure Photos

## Pre-Anesthetic Exam:

This is done the day of the dental, prior to any anesthesia to be certain that your pet will be safe under the anesthetic.

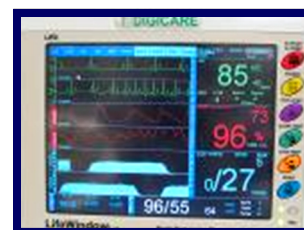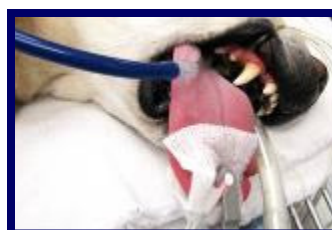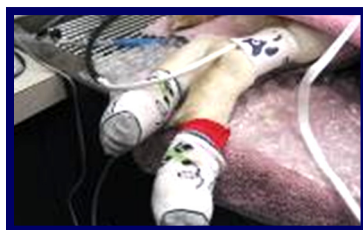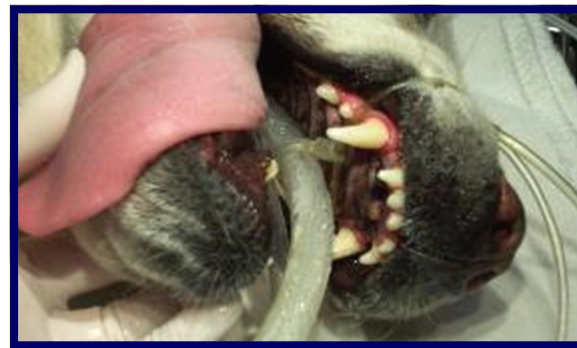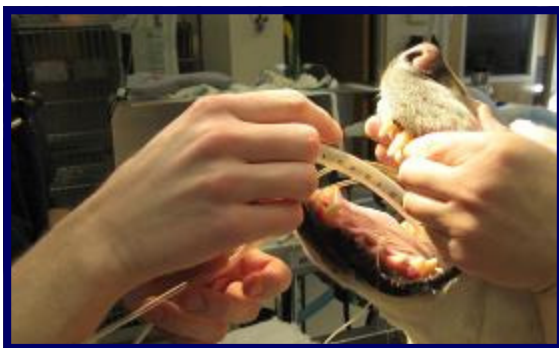For all pets, we will place an intravenous catheter to help us administer the anesthetics and also to keep the patient on I.V. fluid therapy which helps to support body functions.

## I.V. Catheters/Fluids:



## Anesthesia/Monitoring:

We use a variety of different injectable anesthetics depending on the health, age, breed, and species of our patients. We use the most modern and safest procedures for your pet. All patients have an endotracheal tube inserted for delivery of the general anesthetic gas (Isoflurane) and oxygen. For an additional margin of safety utilize a dedicated veterinary assistant and specific equipment to closely monitor the patient while they are under anesthesia.




# Procedure Photos

## Dental Cleaning:

Step 1: Charting– A complete examination of the mouth is performed and recorded in the patient’s chart including the grade of tartar and gingivitis, as well as any abnormalities found for each tooth.

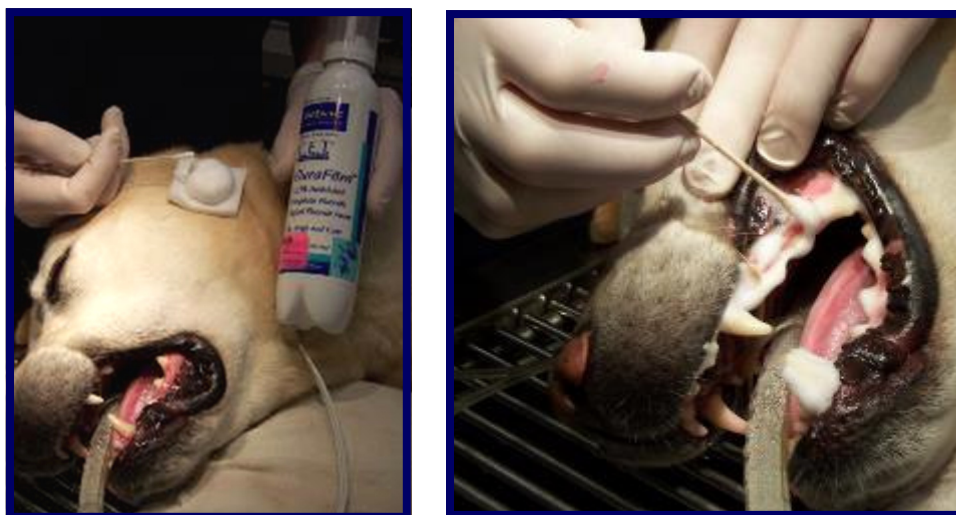Step 2: Scaling– The tartar is removed from both below and above the gum line using an ultrasonic scaler and hand instruments.

Step 3: Polishing– The teeth are polished using a paste to remove any scratches in the tooth enamel caused by scaling.



Step 4: Chlorhexadine Flush– The mouth is rinsed with an antibacterial flush to remove any loose tartar and fight infection.

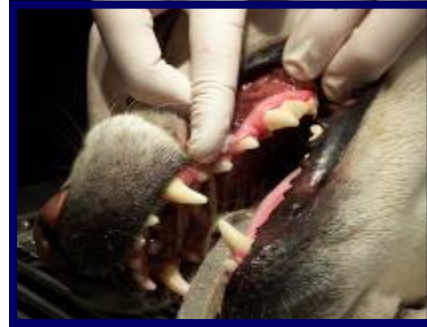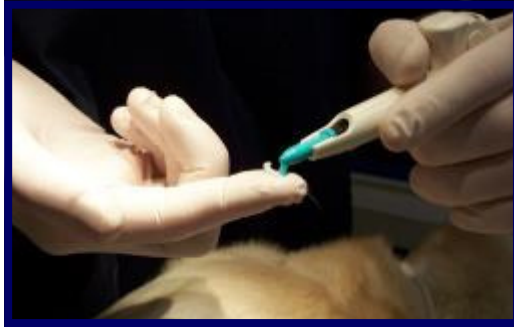Step 5: Fluoride– A fluoride treatment is applied to promote healthy enamel.



# Procedure Photos

## Dental Cleaning:

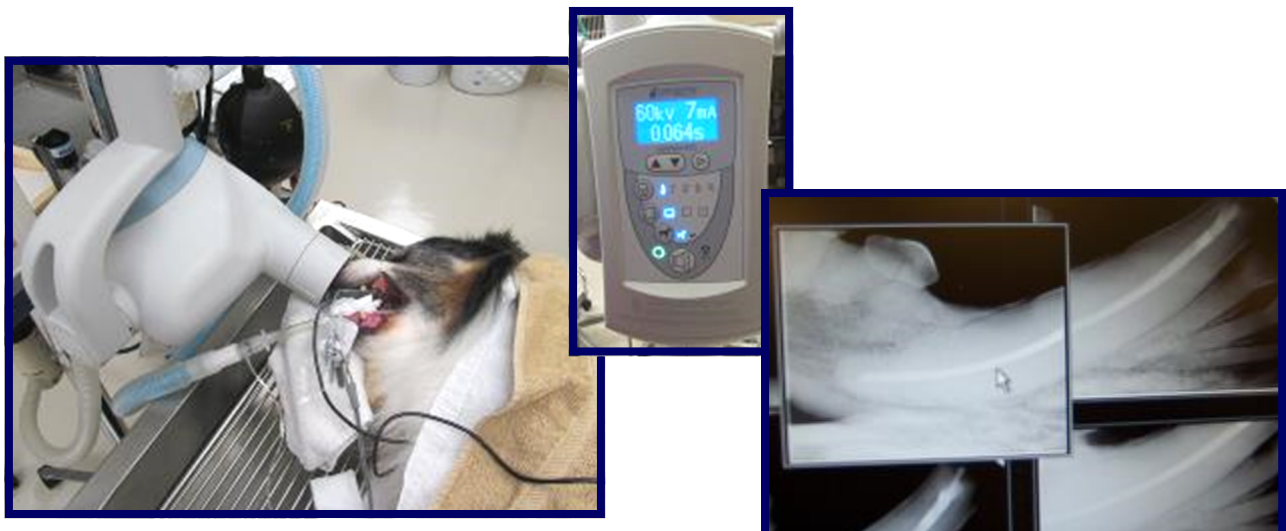
Step 6: Oravet Barrier Sealant– A sealant is applied to the clean teeth to slow the buildup of new tartar.



## Digital Radiographs (X-rays):

As in human dentistry, radiographs are an important factor in evaluating your pet's oral health. Seventy percent of the tooth structure is below the gum line and without dental radiographs it is possible to miss serious underlying problems with your pet's teeth. Dental radiographs help the veterinarian determine healthy from diseased periodontal tissue and in most cases, (approx. 50%) we actually find problems.

Full mouth radiographs are important for patients with crowded teeth, abnormal teeth or teeth that are missing without explanation. Radiographs are also beneficial when the gum line bleeds without probing, a tooth is loose, discolored, or fractured, and/or other abnormalities are noted.





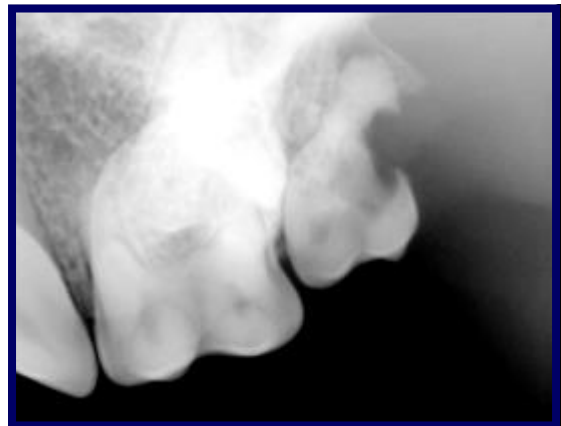
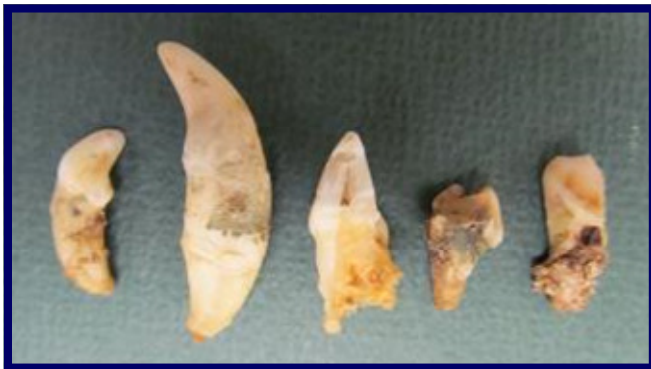# Procedure Photos

## **Torbugesic/Buprenex:**

These are pain medications that are given to most patients if we know there is gum disease, or if we anticipate extractions. We also use local anesthetics when extractions are necessary. If any pet shows signs of pain during, or following the dental cleaning, we will administer additional pain medications. We may also dispense medications for use at home.

## **Extractions:**

The fees for extractions will depend on the number of teeth extracted, as well as the time involved. The fees may not be included in the initial estimate. We will notify you during the procedure if extractions are necessary. The patient will receive local anesthesia to help control pain and desensitize the area(s).



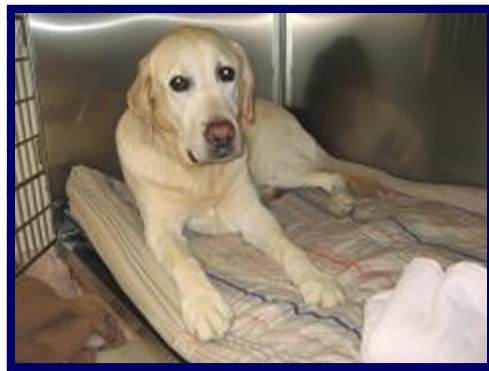## **Antibiotics:**

We generally administer one injection of antibiotics to our patients on the day of the dental cleaning. This is to minimize the effect of the bacteria from the mouth being picked up by the blood supply during the cleaning.

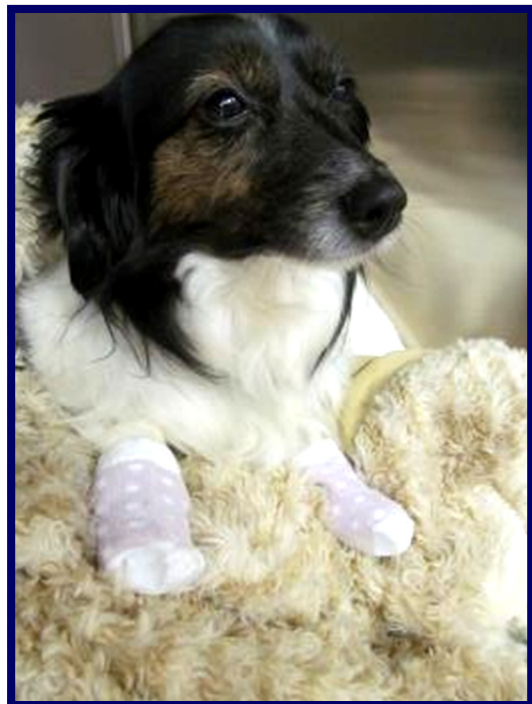# Procedure Photos

## Recovery & Pain Management:

The patient is carefully monitored by a licensed technician during their recovery until they are awake and alert. The patient stays in our hospital for at least a few hours after the procedure so they are fully recovered before sending them home. The technician also goes over the dental findings in detail and any home care instructions with the owner at the discharge appointment.



Warm baby socks and blankets are provided to ensure that our patients are comfortable and cozy while they are waking up along with warm water bottles that keep their body temperature up.



# Home Care

There are a variety of home care approaches that can significantly reduce the level of dental disease your pet experiences. Since pets cannot do these things for themselves, it is up to us as their health care providers and you as owners to provide the best care we can.

## **Things that can be helpful and may be recommended by us:**

1. Daily brushing of the teeth – we can show you how. Use pet toothpaste only (they won't cause stomach upset if they are swallowed), and whichever type of soft bristle brush is easiest for you and your pet.
2. Using an oral rinse, or plaque fighting gel on a daily basis.
3. Using enzymatic dental chews (CET Chews) daily to provide additional plaque fighting action.
4. Feeding a tartar control food such as Hill's Science Diet Prescription t/d dry food.
5. Encouraging your pet to chew on dental chew toys such as the Nylabone and Gumabone products.
6. Inspecting your pet's teeth on a regular basis. Cleaning the teeth in the early stages of plaque build-up is easier, less expensive and healthier for your pet.

**Scheduling the cleanings at least once a year,**  
more frequently if your pet has advanced dental disease;  
in some cases every 3-4 months until the mouth  
has improved, then 2x yearly.

